

Anterior Cruciate Ligament Regeneration in an 8-Year-Old Patient

S. J. Arts, MD¹ M. P. J. Polak, MD² R. P. A. Janssen, MD³

¹ Department Orthopaedic Surgery, Flinders Medical Centre, Adelaide, Australia

² Department of Radiology, Maxima Medical Centre, Eindhoven, The Netherlands

³ Department of Orthopaedic Surgery and Trauma, Maxima Medical Centre, Eindhoven, The Netherlands

Address for correspondence R. P. A. Janssen, MD, Department of Orthopaedic Surgery and Trauma, Maxima Medical Centre, Ds. Th. Fliednerstraat 1, P. O. Box 90052, 5600 PD, Eindhoven, The Netherlands (e-mail: r.janssen@mmc.nl).

J Knee Surg Rep

Abstract

Keywords

- ▶ skeletally immature
- ▶ anterior cruciate ligament
- ▶ regeneration
- ▶ children
- ▶ knee

Ruptured anterior cruciate ligaments (ACL) have doubtful healing potential. This might be better in younger patients. Therefore, treatment of an ACL rupture in the skeletally immature patient knows several strategies. We report the case of an 8-year-old, skeletally immature patient with a midsubstance-ruptured ACL at physical exam and magnetic resonance imaging (MRI). Conservative treatment with a brace led to a stable knee with regeneration of the ACL on both the physical examination and MRI after 5 years. Nevertheless, further research will be necessary to gain better understanding about the biology and healing potential of the ACL.

Each year, the overall incidence of anterior cruciate ligament (ACL) rupture in the United Kingdom is 1:3,000. Among children and adolescents, the incidence increases because of a rising number of young athletes acting at high activity level, together with an increased awareness of such knee injuries amongst doctors.¹ Their incidence is approaching the adult's incidence of ACL ruptures.^{2,3} The majority of patients younger than 12 years with an ACL injury have tibial eminence avulsion. Most patients older than 12 years suffer nonosseous ACL lesions. This can be explained by an increasing rigidity of the skeleton during growth.⁴

The ACL plays a central role in the AP translation and rotation of the tibia. A ruptured ACL often interferes with daily, physiological stability of the knee.⁵ Because of poor spontaneous healing potential, different treatment strategies of the torn ACL have been reported; patients with functional instability often require ACL reconstructive surgery.⁶ Treatment of a ruptured ACL in the skeletally immature patient remains controversial and the current evidence is low.⁷⁻⁹ ACL reconstruction may cause harm to the growth plate with subsequent growth disturbances or deformities, despite techniques that diminish physeal violation.⁴ On the contrary, delayed reconstruction till skeletal maturity increases possible additional intra-articular

knee damage.^{3,10} Conservative treatment requires modification of activities and treatment compliance. This is not an easy task for the young athlete, often competing at a physically demanding level.^{7,8} Preservation of the own, functional ACL after rupture would be an ideal situation. Treating this group of patients is challenging and often a dilemma. Therefore, in the last decades, several researchers in different fields have challenged the regeneration potential of the ACL.^{5,9,11-15}

We report a case with clinical and radiological regeneration of a midsubstance ACL rupture in an 8-year-old patient with conservative treatment.

Case Report

An 8-year-old boy presented at the outpatient clinic with a giving way sensation of the right knee. He played football at recreational level and had suffered a noncontact rotational knee trauma in a football match 3 weeks earlier. At the time of injury, immediate swelling occurred with complaints of giving way. Physical examination showed a healthy child, body mass index of 16 kg/m², with slight swelling of the right knee with full range of motion; Lachman test 6 to 10 mm, anterior drawer test 6 to 10 mm, and a pivot shift 1; IKDC

received
March 29, 2013
accepted after revision
November 6, 2014

DOI <http://dx.doi.org/10.1055/s-0034-1399757>.
ISSN 2326-2729.

Copyright © by Thieme Medical Publishers, Inc., 333 Seventh Avenue, New York, NY 10001, USA.
Tel: +1(212) 584-4662.

License terms



(International Knee Documentation Committee) score D and a Lysholm score of 59. KT1000 knee arthrometer showed a 5-mm difference compared with the uninjured knee.¹⁶ X-ray of the injured knee showed open physis at both femur and tibia. Magnetic resonance imaging (MRI) of the knee demonstrated a midsubstance rupture of the ACL. The posterior cruciate ligament, cartilage, and menisci were intact (→**Fig. 1A**). Conservative treatment with a knee brace (SofTec Genu brace, Bauerfeind, Germany) was initiated. In our practice, ACL reconstructions are only performed in skeletally mature patients, X-ray is the method of control. Skeletally immature patients with an ACL injury are treated by brace for sports activities and pivoting/contact sports are not recommended. He followed a 4-month ACL physiotherapy program consisting of neuromuscular and proprioception training, was advised not to engage in contact sports and to wear the brace during daily activities. The patient was controlled at the outpatient clinic every year with a remarkable compliance with respect to wearing the brace. He wore the brace 3 to 4 hours daily, which was adapted every 2 years due to his growth. Like many Dutch children, he used a bicycle for daily transport to school as well as outside school activities. As such, they train their leg musculature on a daily basis and there was no significant muscular atrophy in our patients at the yearly outpatient visits.

At the age of 14 years, the patient reported no more signs of instability of the knee and did not wear the brace anymore. He was able to perform daily activities and physical exercises such as running and jumping without giving way. He had even played several soccer matches successfully without the brace. Physical examination demonstrated a healthy boy with a body mass index of 20 kg/m², a Lachman test 3 to 5 mm, anterior drawer test 0 to 2 mm, and an absent pivot shift phenomenon. IKDC score A and a Lysholm score of 100; KT1000 measurement showed < 3 mm difference between both knees.¹⁶ MRI of the knee showed a regenerated ACL (→**Fig. 1B**).

At the age of 19 years, MRI's of both the knees are performed as a follow-up of the affected knee and a comparison to the contralateral knee. Again, the ACL shows full continuity and the same density, though is slightly thinner compared with the contralateral knee (→**Figs. 2A and B**).

The patient is performing physically demanding labor work and is not restricted in any way by his knee; he is active in recreational nonpivoting sport and fitness.

Discussion

We present a patient with instability of the knee and a torn ACL on MRI, who, after 6 years of conservative treatment, regained functional stability and a continuous ACL on MRI 6 and 10 years posttrauma. This suggests that a midsubstance ACL tear with discontinuity can actually regenerate, despite the knowledge that the ACL has a poor healing tendency and cases of regeneration are sparse.¹⁴ In vitro, several factors such as synovial tissue, cytokines, growth hormones, the extracellular matrix, and other physiologically active molecules influence regeneration of ligamentous tissue.^{6,11,17} Healing occurs in the following four stages: inflammation and clot formation, epiligamentous regeneration, proliferation, and finally remodeling.¹⁵

There is healing potential of the ACL, but in vivo, the lack of clot formation at the ruptured site of the ACL might disrupt the healing cascade in a very early stage.¹⁴ The clot acts as a deductive and inductive scaffold for further proliferation and healing of the ligament. Several theories have been described to explain clot formation inhibition: intra-articular circulating plasmin in the synovial fluid prematurely breaks down the fibrin clot and the formation of a synovial coverage over both ruptured ends may play a role as well. Furthermore, expression of contractile actin isoform leads to contraction of the ruptured ligament edges causing an increased gap between the ligament parts.^{14,15} Thus, if we can bypass these inhibiting, environmental factors, the ACL does have healing potential. Mastrangelo et al showed in an in vitro animal study, that this healing potential in animals with an immature skeleton is greater than in adolescent or adult animals.¹²

Few authors have described ACL regeneration with conservative treatment. Fujimoto et al concluded that patients with low athletic demands and sedentary occupation, with an intraligamentary ACL lesion but with continuity on MRI, could be treated successfully with an extension block soft brace.⁶ Malanga et al showed that tear location might

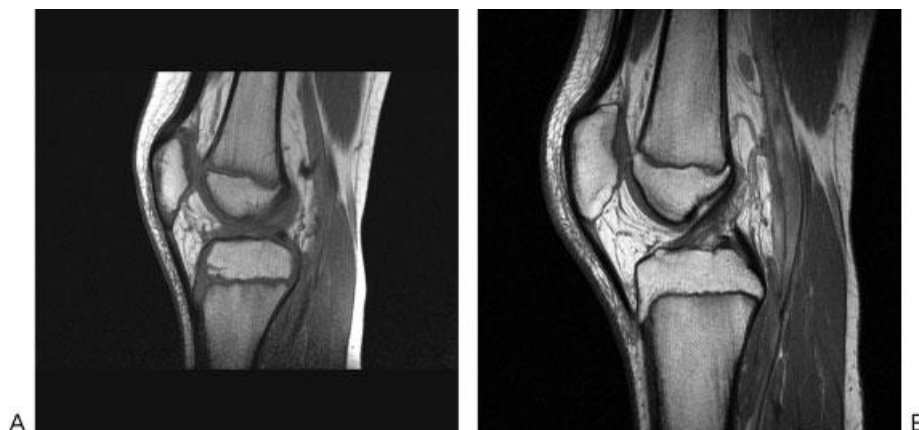

Fig. 1 (A, B) Respectively proton density and T2-weighted magnetic resonance imaging of the right knee at the age of 8 years, showed normal menisci, but a midsubstance anterior cruciate ligament rupture.

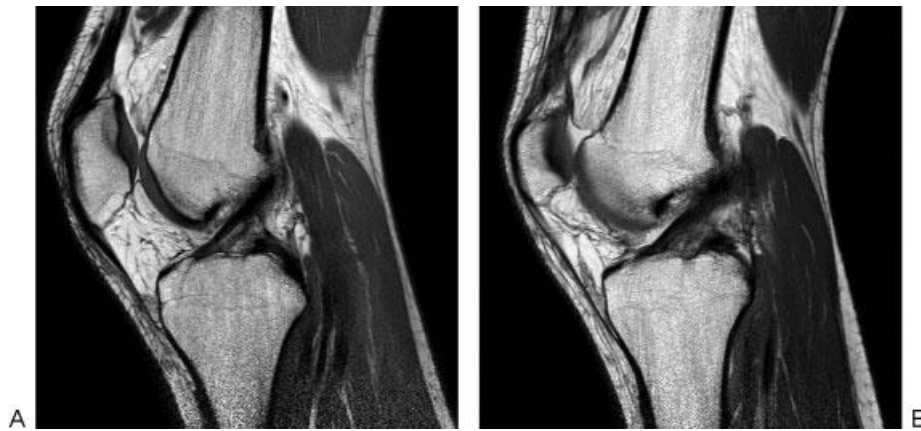


Fig. 2 (A, B) Respectively proton density and T2-weighted magnetic resonance imaging (MRI) at the age of 14 years, 6 years after the initial MRI, showed normal delineation of the anterior cruciate ligament.

influence the healing potential of the ACL; they present a spontaneously healed ACL, ruptured at femoral attachment site. A repeated MRI showed continuity and reattachment of the ACL to the femur.⁵ Similar to our case, the ruptured ligament regained continuity on MRI and demonstrated adequate stability on physical examination. However, the ACL rupture in our patient occurred at the midsubstance level of the ACL. Malanga et al concluded that the tear location at the femoral site, with the majority of the ligament still covered with synovial tissue and a small rupture gap, improved the environment for the reinsertion to the femoral attachment site. A midsubstance tear without continuity tends to lack lengthening and synovial support and has to rely on clot formation as discussed previously. Healing of proximal ACL ruptures has also been reported by Steadman et al.¹³ They described a nonreconstructive, operative “healing response technique” with favorable results in a select group of skeletally immature patients with partial ACL ruptures at the femoral site with functional instability. The femoral insertion was treated with microfracturing to stimulate healing with inducing factors from the bone marrow. Kohl et al had promising results in biological self-healing for repair of complete, acute, and midsubstance ACL ruptures in sheep.¹⁸ The knees of the sheep were treated with microfracturing and collagen was added into the joint. Furthermore, they surgically applied dynamic intraligamentary stabilization. This device acts as a scaffold for the ruptured ligament to grow back to its insertion. In their study, clot formation was biologically stimulated and the space between ruptured ends was minimized by the intraligamentous device. All eight sheep had regained ACL continuity already 3 months postoperatively. In our study, a comparable rupture at midsubstance level occurred, but unlike Egli’s study, our treatment was conservatively with a brace. Our patient presented with a normal ACL ligament on the consecutive MRI at the age of 14 years, 6 years after the first MRI. This interval is much longer compared with the previous mentioned successful cases of healed ACL ruptures, with prove of regeneration already within a year posttrauma.^{6,9,13,18} However, the consecutive MRI with images of a healed ACL in our

patient was performed after 6 years. This does not necessarily mean that it took the ACL 6 years to regenerate; we are not informed about the precise moment of healing. With respect to the physical exam, the knee regained stability in an earlier stage. An exact time frame remains unsure.

In adults, the results of numerous studies have shown that MRI is a highly reliable tool for evaluating the ACL in adults.^{10,19,20} The sensitivity and specificity of a 1.5 T MRI to demonstrate ACL rupture in children and adolescents are 95 to 100% and 88 to 100%, respectively.^{10,20} Standard MRI analysis distinguishes between primary and secondary findings. Primary findings describe the ACL itself and secondary findings are bone bruise and associated lesions. Primary findings are the best indicators for an ACL lesion.²⁰ Furthermore, recent publications show increased accuracy of MRI of knee with respect to single bundle ruptures or partial ruptures. The addition of oblique axial imaging to standard MRI improves accuracy for detecting partial tears and diffusion-weighted MRI attributes to better differentiate between complete and partial ACL ruptures.^{21,22} At the time of injury, we were not able to use such advanced imaging and at this stage, 6 and 10 years posttrauma, this type of additional scanning does not contribute to better understanding of our patient’s ACL regeneration. Concerning therapeutic decision making in pediatric ACL injuries, advanced MRI might be helpful in the future.

In conclusion, we presented the first case report of a skeletally immature patient, who regained functional stability, normal KT1000 score, and regeneration of a midsubstance ACL rupture on MRI by compliant conservative treatment in a brace. Further research will be necessary to gain better understanding about the biology and healing potential of the ACL.

References

- 1 Kerssemakers SP, Fotiadou AN, de Jonge MC, Karantanas AH, Maas M. Sport injuries in the paediatric and adolescent patient: a growing problem. *Pediatr Radiol* 2009;39(5):471–484

- 2 Fehnel DJ, Johnson R. Anterior cruciate injuries in the skeletally immature athlete: a review of treatment outcomes. *Sports Med* 2000;29(1):51–63
- 3 Henry J, Chotel F, Chouteau J, Fessy MH, Bérard J, Moyen B. Rupture of the anterior cruciate ligament in children: early reconstruction with open physes or delayed reconstruction to skeletal maturity? *Knee Surg Sports Traumatol Arthrosc* 2009;17(7):748–755
- 4 Hudgens JL, Dahm DL. Treatment of anterior cruciate ligament injury in skeletally immature patients. *Int J Pediatr* 2012;2012:932702
- 5 Malanga GA, Giradi J, Nadler SF. The spontaneous healing of a torn anterior cruciate ligament. *Clin J Sport Med* 2001;11(2):118–120
- 6 Fujimoto E, Sumen Y, Ochi M, Ikuta Y. Spontaneous healing of acute anterior cruciate ligament (ACL) injuries - conservative treatment using an extension block soft brace without anterior stabilization. *Arch Orthop Trauma Surg* 2002;122(4):212–216
- 7 Mohtadi N, Grant J. Managing anterior cruciate ligament deficiency in the skeletally immature individual: a systematic review of the literature. *Clin J Sport Med* 2006;16(6):457–464
- 8 Chotel F, Henry J, Seil R, Chouteau J, Moyen B, Bérard J. Growth disturbances without growth arrest after ACL reconstruction in children. *Knee Surg Sports Traumatol Arthrosc* 2010;18(11):1496–1500
- 9 Moksnes H, Engebretsen L, Risberg MA. The current evidence for treatment of ACL injuries in children is low: a systematic review. *J Bone Joint Surg Am* 2012;94(12):1112–1119
- 10 Major NM, Beard LN Jr, Helms CA. Accuracy of MR imaging of the knee in adolescents. *AJR Am J Roentgenol* 2003;180(1):17–19
- 11 Cheng MT, Yang HW, Chen TH, Lee OK. Isolation and characterization of multipotent stem cells from human cruciate ligaments. *Cell Prolif* 2009;42(4):448–460
- 12 Mastrangelo AN, Magarian EM, Palmer MP, Vavken P, Murray MM. The effect of skeletal maturity on the regenerative function of intrinsic ACL cells. *J Orthop Res* 2010;28(5):644–651
- 13 Steadman JR, Cameron-Donaldson ML, Briggs KK, Rodkey WG. A minimally invasive technique (“healing response”) to treat proximal ACL injuries in skeletally immature athletes. *J Knee Surg* 2006;19(1):8–13
- 14 Vavken P, Murray MM. The potential for primary repair of the ACL. *Sports Med Arthrosc Rev* 2011;19(1):44–49
- 15 Murray MM, Martin SD, Martin TL, Spector M. Histological changes in the human anterior cruciate ligament after rupture. *J Bone Joint Surg Am* 2000;82-A(10):1387–1397
- 16 Arneja S, Leith J. Review article: Validity of the KT-1000 knee ligament arthrometer. *J Orthop Surg (Hong Kong)* 2009;17(1):77–79
- 17 Higuera Guerrero V, Torregrosa Andrés A, Martí-Bonmatí L, Casillas C, Sanfeliu M. Synovialisation of the torn anterior cruciate ligament of the knee: comparison between magnetic resonance and arthroscopy. *Eur Radiol* 1999;9(9):1796–1799
- 18 Kohl S, Evangelopoulos DS, Kohlhof H, et al. Anterior cruciate ligament rupture: self-healing through dynamic intraligamentary stabilization technique. *Knee Surg Sports Traumatol Arthrosc* 2013;21(3):599–605
- 19 Boks SS, Vroegindewij D, Koes BW, Hunink MG, Bierma-Zeinstra SM. Follow-up of posttraumatic ligamentous and meniscal knee lesions detected at MR imaging: systematic review. *Radiology* 2006;238(3):863–871
- 20 Lee K, Siegel MJ, Lau DM, Hildebolt CF, Matava MJ. Anterior cruciate ligament tears: MR imaging-based diagnosis in a pediatric population. *Radiology* 1999;213(3):697–704
- 21 Ng AW, Griffith JF, Hung EH, Law KY, Yung PS. MRI diagnosis of ACL bundle tears: value of oblique axial imaging. *Skeletal Radiol* 2013;42(2):209–217
- 22 Delin C, Silvera S, Coste J, et al. Reliability and accuracy of qualitative evaluation of diffusion-weighted MRI, combined with conventional MRI in differentiating between complete and partial anterior cruciate ligament tears. *Eur Radiol* 2013;23(3):845–854